

# Toxicity of aqueous extract of *Moringa oleifera* seed powder to Nile tilapia *Oreochromis niloticus* (LINNE 1779), fingerlings

<sup>1</sup>\*E.O. Ayotunde, O.A. Fagbenro<sup>2</sup>, and <sup>2</sup>O.T. Adebayo

<sup>1</sup>Department of Fisheries, Cross River University of Technology, PMB 102, Obubra. Cross River State, Nigeria

<sup>2</sup>Department of Fisheries and Wildlife, Federal University of Technology, PMB 704 Akure, Ondo State, Nigeria

This work determined the toxicity of *Moringa oleifera* seed powder to the most cultivable fish species in Africa, Tilapia, *Oreochromis niloticus*, Fingerlings. *Moringa oleifera* (Moringaceae) seed powder is a good water purifier; it contains polyelectrolytes, which constitute active ingredients in water treatment. The 96-h bioassay was conducted to determine the median lethal concentration (LC<sub>50</sub>) for Nile Tilapia, *Oreochromis niloticus*, fingerlings to aqueous extract of drumstick, *Moringa oleifera* seed. The 24-h, 48-h, 72-h and 96-h of *M. oleifera* applied to *O. niloticus* fingerlings were 252, 251, 242, and 242 mg/l respectively. Toxic reaction exhibited by fish includes erratic movement, air gulping, loss of reflex, discoloration, molting, loss of scale, and haemorrhage. Haematological examination shows an increase in number of blood cell counts (PCV (%), Hb(g/mm<sup>3</sup>) RBC(10<sup>6</sup>/mm<sup>3</sup>), MCHC(T/L), from 17.55±0.7, 5.7±0.3, 3.7±0.1, 1.1±0.1, 31.2±1.7 in control to 23.0±4.2, 7.7±1.5, 3.9±0.1, 2.6±0.3, 34.1±1.4 in higher concentrations, while there was reduction in the number of ESR(%), MCH (pg), and MCV (μ<sup>3</sup>) from 12±1.4, 5.0±0.9 in control to 9±1.4, 3.4±0.9 in higher concentrations in fingerlings tilapia. The histological changes in the gill, skin, liver and kidney includes different level of degeneration of cells, lamellar hyperemia; hypertrophy of gill arch, Shrinkages and dermal erosion and necrosis of skin, while hyperplasia, disarrangement of hepatic cell, necrosis and vacuolation occurred in liver and kidney of fingerling Tilapia *Oreochromis niloticus*. Damages became severe with increasing concentration of *M. oleifera* to fish and time of exposure. There was no significant difference in water quality in the test, the result obtained before the test, during the test and after the test were found closed to the water quality parameters of the control. Results of the test provide baseline information and established safe limit of using aqueous extract of *Moringa oleifera* seed powder in fresh water pond. It was ascertained that aqueous extract of *Moringa oleifera* seed powder did not have adverse effects on water quality.

**Key words:** Toxicity, histological, aqueous extract, *Moringa oleifera*, tilapia, *Oreochromis niloticus*, fingerlings.

## INTRODUCTION

*Oreochromis niloticus* (surface-feeding omnivore) belong to the family Cichlidae; they are the most popular fish for culture in Nigeria. They grow fast, mature quickly; they breed easily, without inducement. They are widely

distributed and they are well accepted by Nigerian. Apart from their special interest for fish biologist and taxonomists, tilapia contribute significantly to African inland water fisheries and are very good species for aquaculture thus this study was carried out (Huisman and Richter 1987; Haylor 1993, Fagbenro et al., 1993).

Many tropical African freshwater aquaculture fishes breed naturally during the flood/ rainy season which

come along with increase in volume and turbidity of water. Moreover, brooder and seeds of commercially important aquaculture species are still collected from the wild. Aluminum sulphate (alum), the convectional coagulant is frequently unavailable and expensive in many sub-Saharan African countries. The efficacy of aqueous extract of *Moringa* seeds for water purification is similar to that of alum. Thus, *Moringa* seed powder, a natural alternative to imported alum in purifying turbid water in fish culture enclosures (earthen ponds, farm dams and irrigation canals) is obtainable locally at a fraction of the cost of alum. Moreover, its use as a replacement of primary coagulant for proprietary coagulants such as alum, *Moringa oleifera* is simple to use and cheap to maintain. Furthermore, recent studies have indicated that alum may be carcinogenic; however no harmful effects have been shown to come from *Moringa* seeds.

Synthetic chemicals and alum has for years been used, as fish disinfectant, and therapeutant. But recently, attention has been shifted to plant chemical, for water treatments and possibly as therapeutic. Recently, *Moringa oleifera* seed powder has been tested and proved to have better performance in purifying turbid water, but little work has been done on the toxicity of *Moringa oleifera* seed powder to some important cultivable fish species. *Moringa* plants are widely available in the tropic. Their leaves, fruits, bark and roots have economic importance for industrial and medicinal uses. Aqueous extract of *Moringa oleifera* seeds are for purifying turbid water in enclosure in Nigeria. Recently, persisted and indiscriminate uses of *Moringa oleifera* seeds as natural coagulant caused mass mortality of fish in different fish enclosure (earthen ponds, farm dams, irrigation canals) in Nigeria.

*Moringa oleifera* Lam. (Moringaceae) (drumstick, horse-radish) tree is a multipurpose tree that thrives in tropics and sub-tropics (Foidl *et al.*, 2001). (Acquaye *et al.*, 2000). Aqueous extract of mature seeds from trees and shrubs of Moringaceae family are effective in clarifying turbid and wastewater in tropical countries (Jahn *et al.*, 1986), especially during rainy season. Pollutants in water significantly affect the ability of fish to detect and respond to chemical stimulus. Feeding, growth, and reproductive performances could also be seriously affected by such polluted habitat. Pollution of aquatic habitat may result in mass fish mortality or their failure to breed in the polluted environment (Lloyd, 1992).

*Moringa oleifera* is widely known and used for hard water softening and water cleansing qualities of their seeds. Muyibi and Evison, (1995) stated that *Moringa oleifera* seeds have the considerable potential to be used in the treatment of hard water, they proved that hardness removal efficiency of *Moringa oleifera* was found to increase with increasing dosage. The more species causing hardness (synthetic water, distilled water spiked with calcium chloride) naturally hard surface water and

ground water). They recommended 650-750mg/l *Moringa oleifera* as threshold for soften synthetic hard water, 900-2400mg/l for calcium hardness of surface and ground water and 300-900mg/l for carbonate hardness. While the effective doses being 30-200mg/litre (Travis *et al.*, 1993)

The dosage required for coagulation, flocculation and sedimentation depends on the turbidities of the water and the number of seeds required for treatment depends on the local average weight of their white kernel. The kernel weight is found to range from 130-320 mg in different clones. Water of low turbidity in the initial and final flood season needs doses equivalent to 50mg/l; water of medium to high turbidities should be 1-1.5seeds/liter (Jahn, 1986; Dutta 1996; Benge, 2003). Eilert *et al.* (1981) isolated 4 $\alpha$  L-rhamnosyloxy-benzyl isothiocyanate, the active ingredient and active antimicrobial agent in the seeds. The seed powder is also be used to harvest algae from wastewaters. During raining seasons, water in fish culture enclosures in Nigeria exhibit turbidity level up to 400 NTU in which Nile tilapia *O. niloticus* are stocked being the most widely cultivated African freshwater fish. *Moringa* seed extracts dose of 75 – 250 mg/l is used to clear water to turbidity <5 NTU. Water pollution/contamination induces pathological changes in fish. Recently, persistent and indiscriminate use of *Moringa* seeds as a natural coagulant caused mass mortality of fish culture enclosure in Nigeria.

Although *Moringa* seeds have been successfully used as water purifier, little has been done on their toxicity to cultivated fishes. Grabow *et al.* (1985) reported the toxic effect of *M. oleifera* seed powder to guppies (*Poecillia reticulata*), protozoa (*Tetrahymena pyriformis*) and bacteria (*Escherichia coli*) and it inhibited acetyl cholinesterase, and sated that *Moringa* seed powder had no effect on coliphage, lactic dehydrogenase. Powdered cotyledon (5mg/liter) affected oxygen uptake of *Tetrahymena pyriformis*, 30-40mg/l disturbed locomotion of guppies and the 96HoursLC<sub>50</sub> for guppies was 196 mg/liter (Grabow *et al.*, 1985). Grabow *et al.* (1985) suggested that the toxic effect may have been due to 4 alpha-L-rhamnosyloxy benzyl isothio-cyanate, a glycosidic mustard oil, it contain an active antimicrobial agent, which is readily soluble in water and non-volatile. (Eilert *et al.*, 1981).

Despite their widespread use, their toxicity and effectiveness to aquatic organisms, particularly fishes, have not been examined. Acute and chronic toxicity test was conducted using aqueous extract of *Moringa oleifera* seeds on the most widely cultivated African freshwater fishes. Therefore, results expected from the toxicity test will provide baseline information and establish limit of using aquatic extract of *Moringa oleifera* seeds in freshwater fishpond. The effect of *Moringa oleifera* on the target organ of the fish would also be determined as persistent usage of the chemical could build up in the

organs of the fish, and the surrounding environment of the fish and this may be deleterious. This study examined the histology of gill, liver and kidney of Nile tilapia, *Oreochromis niloticus*, fingerlings exposed to various sub-lethal concentrations of aqueous extract *M. oleifera* seeds and it will serve as baseline information for the application of the toxicant in the aquatic environment.

## MATERIALS AND METHODS

The experiment was conducted under standard static bioassay procedure (Reish and Oshida 1987, American Public Health Association 1987). This involves carefully controlled environmental conditions as to define the response of the test organism to *Moringa* seed powder. Total 200 live, and healthy fingerlings, Nile Tilapia *Oreochromis niloticus* fingerlings weighing 7.5cm-8.3cm total length; 11.6g-17.6g, identified using taxonomic key of Reed *et al.* (1967), used for the experiment was collected from Ministry of Agriculture and Natural resources, Fisheries department. Alagbaka, Akure in Ondo State, were transported in plastic bowl and acclimated for 1 week in the laboratory, inside transparent rectangular glass tanks (75cm x 45cm x 45cm) container of 121.5 liters capacity, filled with 50 liters unchlorinated well water at Fisheries and Wildlife Laboratory of Federal University of Technology Akure. The fish were fed to apparent satiation twice daily (0900h, 1600h) with a commercial pelleted fish diet containing 35% crude protein during the acclimatization period. Feeding was discontinued 48 hours before the commencement of the experiment, to minimize the production of waste in the test container.

Large quantities of freshly mature seeds of *Moringa oleifera* were obtained from the premises of Federal Prison Yard, Obubra. Cross River State. Nigeria. The seed powder was prepared according to the method described by Price (2000), the seed was sun dried, seed coats and wings were manually removed. The white kernel was ground to a fine powder, using the coffee mill attachment of a moulinex domestic food bender and the powder was kept in desiccators for later use in stock solutions. A stock solution of 1000ml/l (1g/l) of *Moringa oleifera* seed powder was prepared by adding 1.0 g of *M. oleifera* in 1litre of distilled water, according to Olaiya *et al.* (2003). A preliminary range finding test was conducted to determine the toxicity level of *M. oleifera*, seed powder using standard method/procedure (American Public Health Association 1987). In the range finding test, one control and five tests in triplicates, was set up for the experiment. *M. oleifera* seed powder was introduced randomly, and test for 24 hours, the behavior and mortality of the test fishes in each tank was monitored and recorded every 15minutes for the first hour, once every hour for the next three hours and every four hours for the rest 24hours period.

Eighteen (75cm x 45cm x 45cm) glass tanks of 121.5 liters capacity each were filled with 50 liters aerated unchlorinated well water. Ten fingerlings *Oreochromis niloticus* was batch-weighed with a top-loading Mettler balance (Mettler Toledo (K)), and distributed randomly in triplicate per treatment. The glass tanks was covered, there was no aeration, no water change nor feeding throughout the test. This was done prior to the introduction of the toxicant. The toxicant was introduced at least concentration, 150mg/l, 200mg/l, 250mg/l, 300mg/l, and 350mg/l with a control of 0 mg/l in triplicate. The test lasted for 24- hour.

The definitive test was conducted using concentration of *Moringa oleifera* seed powder of 200mg/l, 210mg/l, 220mg/l 230mg/l, 240mg/l, 250mg/l, earlier determined for the range finding test. This test comprised one sub lethal toxicity test according to the standard method/procedures (American Public Health Association 1987).

At the end of the experiment, one fish per treatment, that is, three fish per concentration were sampled after 96hours of exposure for histological analysis; the test organism was killed with a blow on the head, using a mallet and was dissected to remove the kidney, gill, liver and skin. The organs were fixed in 10% formalin for three days after which the tissue was dehydrated in periodic acid Schiff's reagent (PAS) following the method of Hughes & Perry (1976), in graded levels of 50%, 70%, 90% and 100% alcohol for 3 days, to allow paraffin wax to penetrate the tissue during embedding. The organs were then embedded in malted wax. The tissue was sectioned into thin sections (5-7µm), by means of a rotatory microtome and were dehydrated and stained with Harris haematoxyllin-eosin (H&E) stain, Bancroft & Cook (1994), using a microtome and each section was cleared by placing in warm water (38°C), where it was picked with clean slide and oven-dried at 58°C for 30 minutes to melt the wax. The slide containing sectioned materials/tissue was cleared using xylene and graded levels of 50%, 70%, 90%, 95% and 100% alcohol for two minutes each. The section was stained in haematoxyline eosin for ten minutes. The stained slide was observed under a light microscope at varying X100 magnification

## Method of Statistical Analysis

All results were collated and analysed using computerized, probit and logit analysis (Lichfield and Wilcoxon, 1949). The median lethal concentration LC<sub>50</sub> at selected period of exposure, and an associated 95% confidence interval for each replicate toxicity test were subjected to logit and probit analysis (Finney, 1971) using Statistical Package for Social Sciences (SPSS) 15.0 for Windows XP on PC.

**Table 1.** The LC<sub>50</sub> value of *Moringa oleifera* to fingerlings Tilapia *Oreochromis niloticus* for 24hrs, 48hrs, 72hrs, and 96hrs.

TIME	LC <sub>50</sub>
24hours	252mg/l
48hours	251mg/l
72hours	242mg/l
96hours	242mg/l

**Table 2.** The Summary of effects of *Moringa oleifera* on haematological parameters of fingerling tilapia *Oreochromis niloticus*.

CONC/ PARAMETERS	PCV (%)	Hb (g/mm <sup>3</sup> )	ESR (%)	WBC (10 <sup>4</sup> /mm <sup>3</sup> )	RBC (10 <sup>6</sup> /mm <sup>3</sup> )	MCH (pg)	MCHC (T/l)	MCV (μ <sup>3</sup> )
T <sub>0</sub> (0mg/l)	17.5±0.7	5.7±0.3	12±1.4	3.7±0.1	1.1±0.1	5.0±0.9	31.2±1.7	1603±191.8
T <sub>1</sub> (200mg/l)	15.5±0.7	5.4±0.1	12.5±0.7	4.4±0.1	1.2±0.1	4.3±0.3	33.7±2.1	1277±150.8
T <sub>2</sub> (210mg/l)	19.5±0.7	6.4±0.2	11.5±0.7	3.4±0.2	1.4±0.1	5.4±1.0	33.6±10.0	1733±808.3
T <sub>3</sub> (220mg/l)	20.0±8.5	6.7±2.8	11.53.5	4.6±0.8	1.8±1.4	6.5±4.9	38.6±18.4	1623±522
T <sub>4</sub> (230mg/l)	17.5±6.4	5.9±2.1	11.5±3.5	4.6±1.1	1.7±1.3	3.6±1.7	40.8±10.5	891±210
T <sub>5</sub> (240mg/l)	14.5±0.7	5.0±0.4	11±0.0	4.7±0.1	1.1±0.3	4.7±2.0	37.5±6.0	1244±299
T <sub>6</sub> (250mg/l)	23.0±4.2	7.7±1.5	9±1.4	3.9±0.1	2.6±0.3	3.4±0.9	34.1±1.4	857±63.9

**Table 3.** Behavioral of Fingerling Tilapia (Range finding test)

Behavior/ Exposure Time	12hrs.	16hrs.	20hrs.	24hrs.
Concentrations	0 150 200 250 300 350	0 150 200 250 300 350	0 150 200 250 300 350	0 150 200 250 300 350
Loss of reflex	- - - - + +	- - - - + +	- - - - + +	- - - - + +
Molting	- - - - + +	- - - - + +	- - - - + +	- - - - + +
Discoloration	- - - - + +	- - - - + -	- - - - + -	- - - - - -
Air gulping	- + + + + +	- + + + + +	- + + + + -	- + + + + -
Erratic swimming	- - - - + +	- - - - + +	- - - - + +	- - - - + +
Loss of scale	- - - - - -	- - - - - -	- - - - - -	- - - - - -
Haemorrhage	- - - - - -	- - - - - -	- - - - - -	- - - - - -

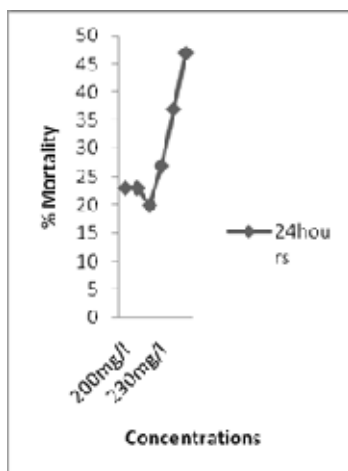
## RESULTS AND DISCUSSION

The 96-h LC<sub>50</sub> of *Moringa oleifera* to fingerlings tilapia *Oreochromis niloticus* is 242mg/l with 95% confidence limit of 2.97 mg/l-5.59 mg/l, and the maximum toxicant admissible concentrations were 2.42mg/l-24.2mg/l established for *O. niloticus* fingerling was derived by multiplied a constant 0.01 – 0.1 by 96-h LC50 (Koesomadinata 2000), while total mortality occurred in 350 mg/l of *M. oleifera* to *O. niloticus* fingerlings as presented in Table 1 and figures 1-4. Annune et al. (2002), reported lower concentration of Ringworm plant *Senna alata*, used in poisoning water bodies for fish capture in Benue State of Nigeria, the 96-h LC<sub>50</sub> for juvenile tilapia *Oreochromis niloticus* was 13.93 mg/l, Indicated that the extract causes sub acute effect.

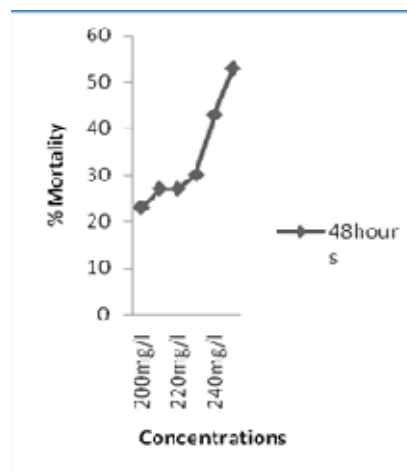
The toxicity of *Moringa oleifera* to *O. niloticus* is higher than the result of Wade et al. (2002) who reported that the 96hLc50 of 0.19mg/l<sup>-1</sup>, for the Nile tilapia *Oreochromis niloticus*, exposed to the toxicity of cassava

(*Manihot esculenta*), the reason may be as a result of higher toxicant concentration in cassava effluent. Santhakumar and Balaji (2000) reported the acute toxicity of an organophosphorus insecticide monocrotophos to the fresh water fish *Anabas testudineus* and stated that the, 24hr, 48hr, 72hr, and 96HoursLC<sub>50</sub> were found to be 22.65, 21.2, 9.75, and 19ppm respectively. The safe concentration of monocrotophos was 0.19 ppm. Muniyan and Veeraraghavan (1999) reported the effect of insecticide, ethofenprox to Nile Tilapia *Oreochromis mossambicus*, using a static bioassay method, the median lethal concentration for 3, 6, 12, 24, 48, and 96Hours were 2.03, 1.95, 1.90, 1.85, 1.79, 1.76, and 1.74 ppm, respectively.

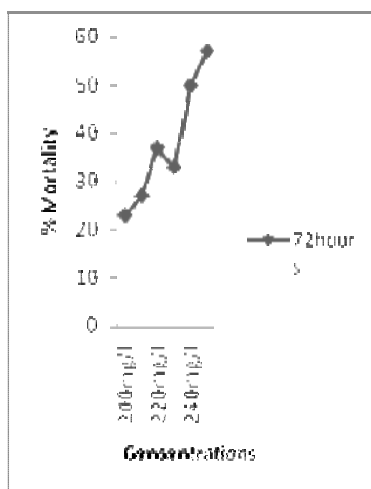
The behavioral response observed shows that fingerlings of Tilapia *Oreochromis niloticus* showed variations in their tolerance to aqueous extracts of *Moringa oleifera* Table 2 and 3: upon addition of the



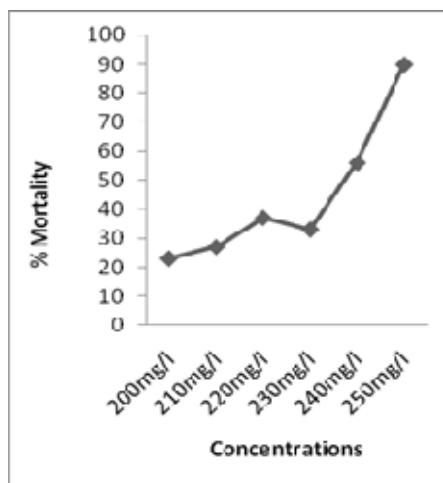
**Figure 1.** Determination of LC<sub>50</sub> for Fingerlings Tilapia (*O. niloticus*) 24hrs



**Figure 2.** Determination of LC<sub>50</sub> for Fingerlings Tilapia (*O. niloticus*) 48hrs



**Figure 3.** Determination of LC<sub>50</sub> for Fingerlings Tilapia (*O. niloticus*) 72hrs



**Figure 4.** Determination of LC<sub>50</sub> for Fingerlings Tilapia (*O. niloticus*) 96hrs

**Figure 1-4.** Determination of LC<sub>50</sub> using graphical method USEPA, (2000)

toxicant, the fish showed various toxic reactions such as erratic movements, air gulping, molting, while increase in concentration and exposure time resulted in loss of scale and haemorrhage. This report agree with the work of many authors (Muniyan and Veeraraghavan 1999, Santhakumar and Balaji 2000, Ayuba and Ofojekwu 2002 and Chung-Min Liao *et al.* 2003), who work on the toxicity of different chemical to freshwater fishes.

There is significant difference ( $P < 0.05$ ) in the value of blood parameters, of fingerlings *O. niloticus* after

exposure to 96-h *Moringa oleifera* as shown in Table 4. The result of haematological parameters of fingerlings tilapia showed significant difference in higher concentrations. The pack cell volume increased from  $17.5 \pm 0.7$  in the control to  $23.0 \pm 4.2$  in concentration of 250mg/l *Moringa*/ liter of water. While there is an increase in the value of blood cell counts, the blood parameter shows an increase of  $3.7 \pm 0.3$  ( $10^4 \text{mm}^3$ ), to  $3.9 \pm 0.1$  ( $10^4 \text{mm}^3$ ),  $1.1 \pm 0.1$  ( $10^6 \text{mm}^3$ ), to  $2.6 \pm 0.3$  ( $10^6 \text{mm}^3$ ). The results presented in Table 1 show the histological

**Table 4.** Behavioral of Fingerling Tilapia (Definitive Test)

Behavior/ Exposure Time	24hrs	48hrs	72hrs	96hrs
Concentrations	200 210 220 230 240 250	200 210 220 230 240 250	200 210 220 230 240 250	200 210 220 230 240 250
Loss of reflex	- - - + - -	- - - - - -	- - - - - -	- - - - - -
Molting	- - - - + +	- - + - - -	- - + - - -	- - - - - -
Discoloration	- - - + + +	+ + - + + +	+ + + + + +	+ + + + + +
Air gulping	+ + + + + +	+ + + + + +	+ + + + + +	+ + + + + +
Erratic swimming	- - + + + +	- - - - + -	- + + + + -	- - - + + -
Loss of scale	- - - - - -	- - - - - -	- - - - - +	- - - - + +
Haemorrhage	- - - - - -	- - - - - -	- - - - - -	- - - - + +

Key: - = not present  
+ = Present

**Table 5.** Result of Histopathological changes observed *Oreochromis niloticus* fingerlings exposed to *Moringa oleifera*.


CONC. (mg/l)	GILLS	SKIN	LIVER	KIDNEY
CONTROL	Normal gill filament, there is no pathological lesion observed.	Normal skin, there is no pathological lesion observed	Normal liver, there is no pathological lesion observed	Normal kidney, there is no pathological lesion observed
200	Degenerate filaments and necrosis observed on the gill arch	Normal skin, there is no pathological lesion	Disorientation of the liver parenchyma structure	Vacuolation and shrinkages of cell observed
210	Vacuolation of the gill arch, total removal of lamellae	Normal skin, there is no pathological lesion	Disorientation of the liver parenchyma structure	Shrinkages of cell
220	Complete degeneration of filamentous structure of the gill arch.	Normal skin, there is no pathological lesion	Vacuole formation, and the cell hepatocyte enlarged.	Shrinkages of cell
230	Complete degeneration of filamentous structure of the gill arch.	Necrosis of the skin	Hyperplasia and disorientation of hepatic cell.	The karyolysis of the hepatocyte
240	Complete degeneration of filamentous structure of the gill arch.	Removal of dermal layer and hypertrophy of the skin observed	Vacuole formation, Shrinkages of cell observed.	Complete degeneration of cell.
250	High degenerated gill arch, filament and lamellae.	Removal of dermal layer and hypertrophy of the skin observed	Shrinkages of cell observed	Complete degeneration of cell

changes observed in fingerlings Tilapia *Oreochromis niloticus* exposed to different concentration of aqueous extract of *Moringa oleifera* at different time interval.


The result presented in table 5 and figure 1-8 shows the histological change observed in fingerling tilapia treated with 200mg/l, 210mg/l, 220mg/l, 230mg/l, 240mg/l, 250mg/l and 0mg/l as control. Histopathological changes in the gill, skin, liver, and kidney were observed for all the treatments. Lesions were essentially similar for all treatments and exposure time, although the intensity of cell damage increased with increasing concentration and time of exposure. The changes in gill structure shows

degenerated filaments in the gill arch in fish treated with 200mg/l *M. oleifera* seed powder. Vacuolation of the gill arch and total removal of lamellae occurred in fish treated with 210mg/l of *M. oleifera* seed powder, complete degeneration of filamentous structure of the gill arch, observed in fish treated with 220mg/l and 230mg/l of *M. oleifera*. While, there was complete degeneration of filamentous structure of the gill arch in fish treated 240mg/l *M. oleifera*. High degenerated gill arch, filament and lamellae (Figure. 2) observed in highest concentration of 250mg/l of *M. oleifera* treated fish.

The normal histology of the skin structure of fingerling




**Figure 1.** Histopathology of gill showing normal gill filament, there is no pathological lesion observed



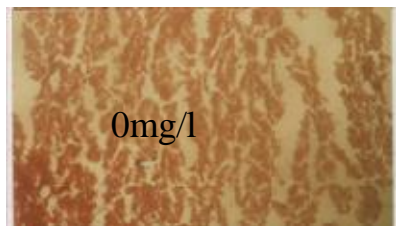
**Figure 2.** Histopathology of gill showing high degenerated gill arch, filament and lamellae.




**Figure 3.** Histopathology of skin showing normal skin, there is no pathological lesion observed



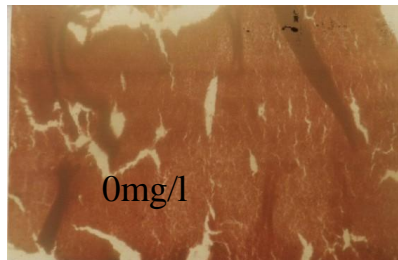
**Figure 4.** Histopathology of skin showing the removal of dermal layer and hypertrophy of the skin observed



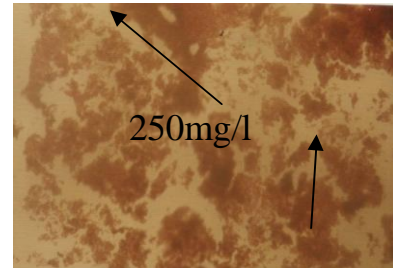
**Figure 5.** Histopathology of liver showing normal liver, there is no pathological lesion observed



**Figure 6.** Histopathology of liver showing the shrinkages of cell observed



**Figure 7.** Histopathology of kidney showing normal kidney, there is no pathological lesion observed



**Figure 8.** Histopathology of kidney showing complete degeneration of cell

tilapia *Oreochromis niloticus* exposed to lower concentrations of *M. oleifera* of 0 mg/l, 200 mg/l, 210 mg/l and 220 mg/l) aqueous extract of *M. oleifera*. Necrosis of the skin was observed in higher concentration 230mg/l in *M. oleifera* treated fish. While the removal of dermal layer and hypertrophy of the skin observed was observed in highest concentration of 240mg/l and 250mg/l in *M. oleifera* treated fish.

The normal histology of the liver structure observed in 0mg/l of *Moringa oleifera*. Disorientation of the liver parenchyma structure was observed in sublethal concentration of 200mg/l of *M. oleifera* treated fish. Disorientation of the liver parenchyma structure occurred in concentration of 210mg/l of the toxicant. Hyperplasia and disorientation of hepatic cell was observed in concentration of 220mg/l. Vacuole formation, and the cell hepatocyte enlarged in concentration 230mg/l in *M. oleifera* treated fish. Disorientation of the liver parenchyma structure, vacuole formation and Shrinkages of cell was observed in high concentration of *M. oleifera* treated fish. Shrinkage of cell was observed in highest concentration of 250mg/l of *M. oleifera* treated fish (Figure 4). Babatunde *et al.* (2001) determined the acute toxicity of paraquat (1, 1-dimethyl-4-4-bipyridinium dichloride) to fingerlings of *Oreochromis niloticus* (Trewavas). Histopathology of gills, of the fish exposed to 12.00mg/l and 14.20mg/l showed a dose dependent destruction of the architecture of the lamellae, filament hyperplasia and atrophy, leading to impairment in oxygen uptake. Behavioral response to paraquat includes loss of equilibrium, agitated swimming, air gulping, hemorrhaging of the gill, pectoral and pelvic fins, period of quiescence and finally death.

Visoottiviset *et al.* (1999) studied the histopathological effects of triphenyltin hydroxide (TPTH) on the liver kidney and gill on one month old of Nile tilapia (*Oreochromis niloticus*) by light microscopy method. Two concentrations of TPTH were used: 1 mg l<sup>-1</sup> and 3 mg l<sup>-1</sup>. The fish were sacrificed at the end of one, two, three and four months. The results showed that the hepatocytes underwent a variety of changes from congestion and dilatation of sinusoidal space, pallor of cytoplasm, vacuolation and accumulation of hyaline droplets. Sub capsular and scattered focal necrosis was also observed. In the kidney, hydropic degeneration and accumulation of hyaline droplets in the tubular epithelial cells were noted. In addition, a congestion of per tubular capillaries and detachment of tubular epithelial cells were observed. In more severe case there was a collapse of glomerular capillary tuft with a widening of the Bowman's capsule. There were some changes in the gill filaments and lamellae, namely hyperplasia of the covering gill epithelium, congestion of gill capillaries and vessels, and aneurismal formation of gill lamellar capillaries. These alterations were time- and dose-dependent (Visoottiviset *et al.* 1999)

The normal histology of the kidney structure observed

in fingerling tilapia *Oreochromis niloticus* exposed to 0mg/l, 210mg/l of *M. oleifera*. Shrinkages of cell occurred in concentration 220mg/l of *M. oleifera* treated fish. The karyolysis of the hepatocyte was observed in concentration of 230mg/l. While complete degeneration of cell was observed in highest concentration of 240 and 250mg/l (Figure 8) of *Moringa oleifera* treated fish. The histological responses observed were qualitatively similar to those previously reported for formalin-treated salmonids (Smith and Piper 1972; Brussle 1996), the primary pathological changes were found in fish exposed to 300 ppm and higher concentration of formalin.

## ACKNOWLEDGEMENTS

The authors are grateful to Mr Olarewaju Johnson (Senior Technologist, Post Graduate Laboratory) and Mr J.O Adesida (Senior Technologist, Pathology Laboratory, Federal University of Technology Akure) for analysing the samples.

## REFERENCES

- Acquaye D, Smith M, Letchamo W, Simon J (2000). A snopp: The miracle tree: Center for new use agriculture and natural plant product. Rutgers Uni., Cook College, 59 Dudley Road, Foran Hall, New Brunswick.
- Annune PA, Ekpendu TOE, Ogbonaya NC (2002). Acute toxicity of aqueous extract of *Senna alata* to juvenile Tilapia *Oreochromis niloticus* (TREWAVAS). Bk. Of Abstract FISON 18<sup>th</sup>- 22<sup>nd</sup> nov. Uyo Nig
- APHA (1987). Standard method for examination of wastewater and water (17<sup>th</sup> ed. Washington D.C.) 8910pp.
- Ayuba VO, Ofojekwu PC (2002). Acute toxicity of the Jimson's weed (*Datura innoxia*) to the African catfish (*Clarias gariepinus*) Fingerlings AJOL. J. Aqua. Sci. Vol.17 No. 2
- Babatunde MM, Oladimeji AA, Balogun JK (2001). acute toxicity of gramoxone to *Oreochromis niloticus* (Trewava) in Nigeria. Water, Air, soil pollut. Vol.131, No.1-4 Pp11-10
- Benge M (2003). Moringa seeds used in water purification: Originally appeared in: AMARATH TO ZAI HOLE. ECHO' KNOWLEDGE BANK. USA.
- Brulé J, González i anadon, G (1996). The structure and function of fish liver. In: *Fish morphology*, (eds) J.S.D. Munshi & H.M. Dutta. Science Publishers Inc.
- Bancroft JD, Cook HC (1994). Manual of histological techniques and their diagnostic application. Churchill Livingstone, London. pp.289-305.
- Chung-Min Liao, Bo-Ching Chen, Sher Singh, Ming-Chaalin, Chen-Wuing LIU, Bor-Cheng Han (2003). Acute toxicity and bioaccumulation of arsenic in tilapia (*Oreochromis mossambicus*) from a blackfoot disease area of Taiwan. *Environ. Toxicol.* Vol. 18. No4. Pp252-259
- Dutta HM (1996). A composite approach for evaluation of the effects of pesticides on fish. In: *Fish morphology*, (eds) J.S.D. Munshi & H.M. Dutta. Science Publishers Inc.
- Elilert U, Wolter B, Nahrstedt (1981). The antibiotic principle of *Moringa oleifera* and *Moringa stenopetala*. *Planta Medica* 42, 55-61
- Fagbenro OA, Adedire CO, Owoseni EA, Ayotunde EO (1993). Studies on the biology and aquacultural potential of feral catfish. *Heterobranchus bidorsalis* (Geoffroy Saint Hilaire 1809) (Clariidae). *Tropical zoological zoology*, 6:67-79.
- Foidl N, Makkar HPS, Becker K (2001). The potential of *Moringa oleifera* for agricultural and industrial uses, pp 45-76, In: The

- Miracle Tree: The Multiple Uses of Moringa (Ed) Lowell J. Fuglie, CTA, Wageningen, The Netherlands.
- Finney DJ (1971). Statistical method in biological assay, 2<sup>nd</sup> Ed. Hafner Pub. Co. New York. N.Y. 68p. Probit analysis. Cambridge University Press London, England.
- Grabow WOK, Slabbert JL, Morgan WSG, Jahn SAA (1985). Toxicity and mutagenicity evaluation of water coagulated with *Moringa oleifera* seed preparation using, fish protozoan, bacterial coliphage, enzyme and salmonella assay. CAB Abstract 1984-1986.
- Jahn SAA (1986). Monitored water coagulation with *Moringa oleifera* seeds in village household. J. Analytic Sci. 1 p.40-41 N- Tropag & Rural.
- Haylor GS (1993). The case of the African catfish, *Clarias gariepinus* Burchell. Clariidae. A comparison of the relative merit of tilapia fishes especially *Oreochromis niloticus* L and *C. gariepinus* Burchell 1822, for African Aquaculture. Aquaculture Fish MGT 20: 285-297.
- Huisman EO, Richter CJ (1987). Reproduction, growth, health control and aquacultural potential of the African catfish *Clarias gariepinus* Burchell 1822. Aquaculture 63: 1-14.
- Hughes GM, Perry SF (1976). Morphometric study of trout gills: A light microscopic method for the evaluation of pollutant action. J. Exp. Biol. 63: 447-460.
- Koesomadinata S (2000). Acute toxicity of the insecticide formulation of endosulphan, chlorpyrifos, and chlorfluazuron to three freshwater fish species and freshwater giant prawn. Jurnal penelitian perikanan Indonesia. Vol.4(3-4) Pp36-43.
- Litchfield JT, Wilcoxon F (1949). A simplified method of evaluation of dose effect experiment. J. pharm. exp. Theraput. Vol. 96 pp 99 – 113.
- Muyibi SA, Evison LM (1995). *Moringa oleifera* seeds for softening hard water. Water Research 29: No4, pp1099-1105.
- Reish DL, Oshida OS (1987). Manual of methods in aquatic environment research. Part 10. Short term static bioassay. FAO Fisheries Technical Paper No 427. Rome. 62 Pages.
- Reed W, Burchard J, Jonathan, Ibrahim Y (1967). Fish and fisheries of Northern Nigeria. Min. of Agric. Northern Nigeria.
- Lloyd R (1992). *Pollution and Freshwater Fish*, pp. 77-85. Fishing new books.
- Muniyan M, Veeraraghavan K (1999). Acute toxicity of ethofenprox to the fresh water fish *Oreochromis mossambicus* (PETERS). J. Environ. Biol. Vol.20 No.2pp153-155.
- Olaifa FE, Olaifa AK, Lewis OO (2003). Toxic stress of lead on *Clarias gariepinus* (African catfish) Fingerlings) African Journal of Biochemical Research, Vol. 6; 101-104.
- Price ML (2000). The *Moringa* tree. ECHO Dev. Note. U.S.A. RAHMAN, M. N., Holssain, Z., Mollah, M. F.A. & Ahmed, G.U. (2002). IN Naga, The ICLARM Quarterly vol. 25, No.2. Edited by Gupta M.V.Santhakumar M, Balaji M (2000). Acute toxicity of an organophosphorus insecticide monochrotophos and its effects on behaviour of an air breathing fish, *Anabas testudineus* (BLOCH). J. Environ. Biol. Vol. 21, No2. Pp21-123.
- Smith CE, Piper EG (1972). The pathological effects in formalin-treated rainbow trout (*Salmo gairdneri*). J. Fish Res. Board Can.29: 328-329.
- Travis VE, Folkard GK, Sutherland JP (1993). Preliminary investigations into the use of sereds from the tree *Moringa oleifera* as a treatment for wastewaters. Leicester University Engineering Research Report, 92-3, pp.34.
- USEPA (2000). Methods for measuring the acute toxicity of effluents to freshwater and marine organisms. 4<sup>th</sup> ed. Environmental Monitoring and support Laboratory, U.S. Environmental Protection Agency, Cincinnati, Ohio. EPA 600/4-85/013.
- Visoottiviset P, Thamamaruitkum T, Sahaphong S, Reiengroipitak M, Kruatrachua (1999) Histopathological effect of triphenyltin hydroxide on liver, kidney, and gill of Nile tilapia (*Oreochromis niloticus*). Applied organometallic chemistry Vol.13 issue 10 Pp749-763.
- Wade JW, Omoregie E, Ezenwaka (2002). Toxicity of cassava (*Manihot esculenta* CRANTS) effluent on the Nile Tilapia *Oreochromis niloticus* (L) Under laboratory condition. AJOL. J Aqua. Sci. Vol. 17. No2.