

Xanthomatosis and Orthopaedics: Review of literature

Nishikant Kumar*, Sumit Anand, Prof. Chandrashekhar Yadav, Prof. Himanshu Kataria, Pawan Kumar, Sanjay Yadav

Lady Hardinge Medical College and RML Hospital, New Delhi

ABSTRACT

Xanthomas are tumors composed of lipid laden foam cells, posing only a cosmetic problem in most patients. However, they may be the only indicator of an underlying lipid disorder which in turn is potentially fatal. We report the rare type IIa hyperlipoproteinemia in a 6yr old child from an orthopaedic view point and the role of an orthopaedic surgeon from diagnosis to management.

Keywords: Xanthomatosis, Orthopaedics, Case Report.

INTRODUCTION

A 6 year old non-obese boy from Chhapra district of Bihar, was brought to the outpatient department by his parents with complaints of multiple painless, nodular skin lesions over bilateral knees, elbows and tendoachilles and popular lesions over axilla, gluteal region and near eye lids for 2 years. The lesions had an insidious onset and progressed gradually over 18months to the present size, without any associated complication of pain or functional limitation except for cosmetic disfigurement. His parents were not sure of which swelling appeared first. Associated history of trauma, prolonged fever, jaundice, pruritis, bone pains, weight loss, seizure, transient loss of consciousness, chest pain or similar family history were ruled out. His parents had non consanguineous marriage.

On Physical examination child had normal higher mental functions. He had abnormal faces with frontal bossing, depressed nasal bridge and protruding maxilla (Fig.1). Both the eyes had arcus juvenilis with xanthelesma on the outer canthus (Fig 2 and 3). His systemic examination was unremarkable. Detailed dermatological evaluation revealed large, skin colored, nodular subcutaneous swellings called tuberous xanthomas over bilateral anterior knee and over extensor aspect of bilateral proximal forearms (Fig.4 and 5). The xanthomas were multilobular, nontender, well-defined, smooth surfaced, soft in consistency with normal

overlying skin. There were tendinous xanthomas over bilateral tendoachilles, plaque like eruptive xanthomas over bilateral axillae and gluteal region. There were no lesions in interdigital webs of hands and feet. None of the joints have contracture and restriction of movements.

Laboratory examination revealed microcytic normochromic anemia (Hb-9.5gm %) with abundant platelets (48 x 10000/cumm) with normal Liver, Kidney function tests, serum electrolytes and coagulation profile. Lipid profile was deranged with a markedly increased total cholesterol level of 706mg/dl (N-130 to 230mg/dl) and LDL cholesterol level of 635mg/dl (N- 50 to 150mg/dl), though HDL, VLDL and triglyceride levels were normal. His father and mother also had a moderately high total cholesterol level (F-300mg/dl, M-242mg/dl) and LDL cholesterol level (F-231mg/dl, M-183mg/dl), though both of them were asymptomatic. Rest of the workup which included chest x-ray, electrocardiogram, 2D - ECHO of the heart, Ultrasonography of the abdomen and chest and MRI of the brain was normal.

FNAC of the knee swelling was inconclusive but that of the elbow swelling showed foamy histiocytes in chronic inflammatory cells along with multinucleated histiocytes (Fig.6).

A presumptive diagnosis of xanthomatosis with Type IIa hyperlipoproteinemia was made based on clinical and

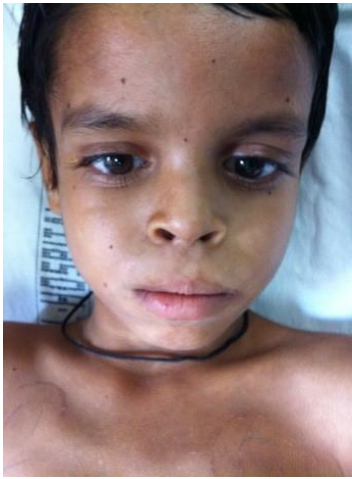

Figure 1.

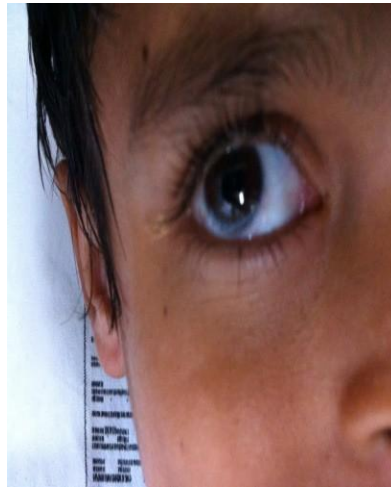

Figure 2.

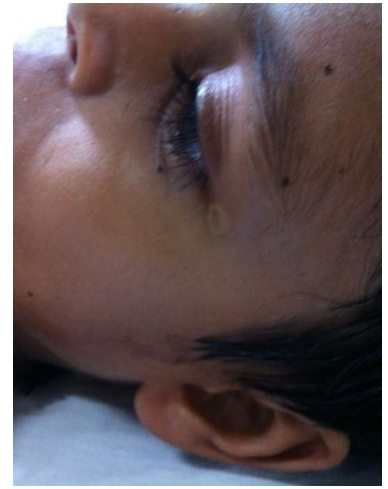


Figure 3.

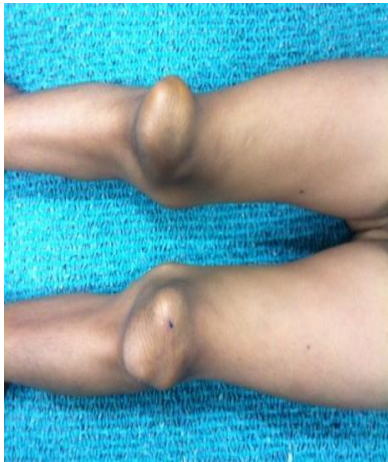

Figure 4.

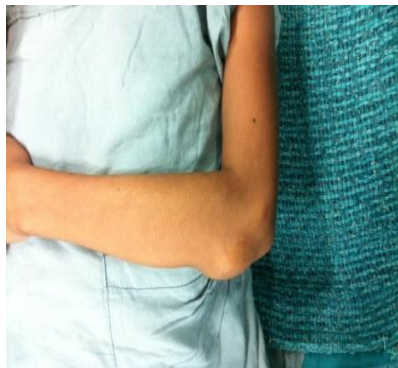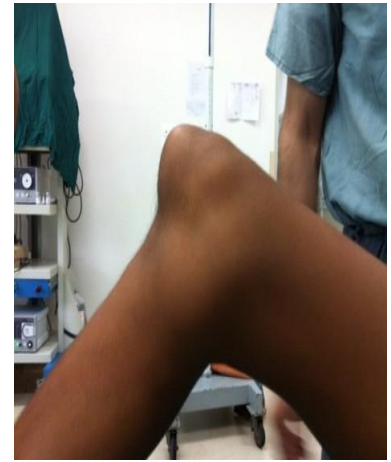

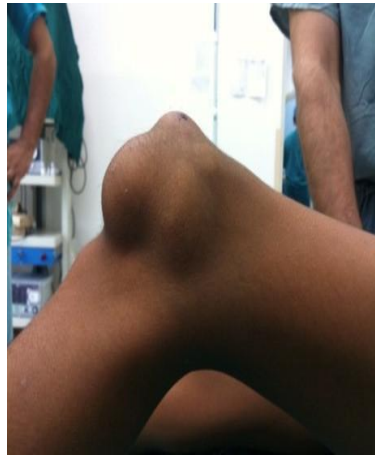
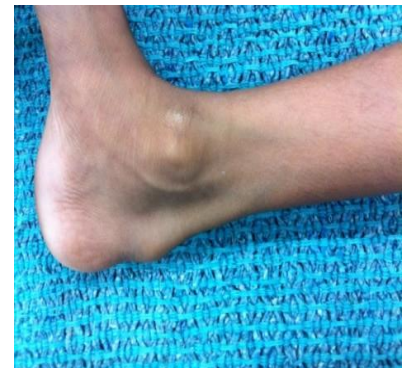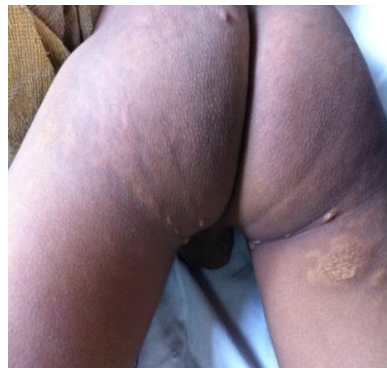Figure 5.



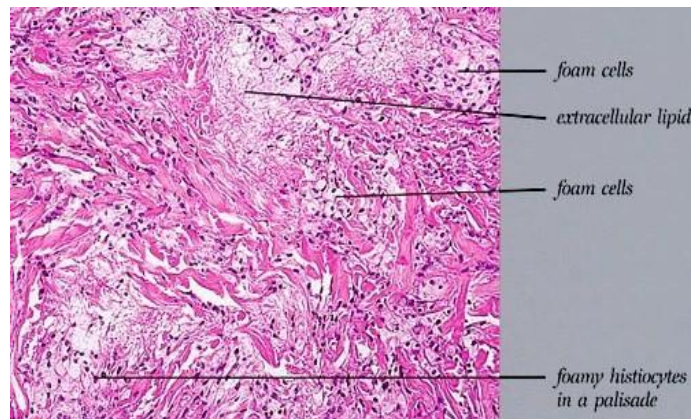


Figure 6.

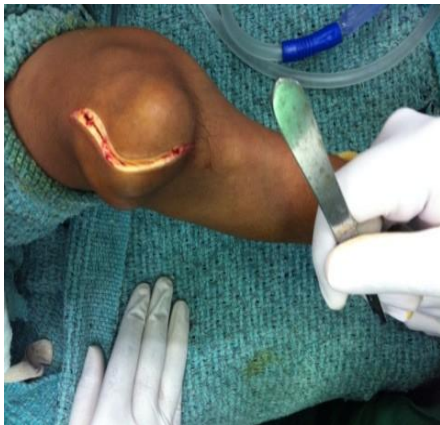

Figure 7.

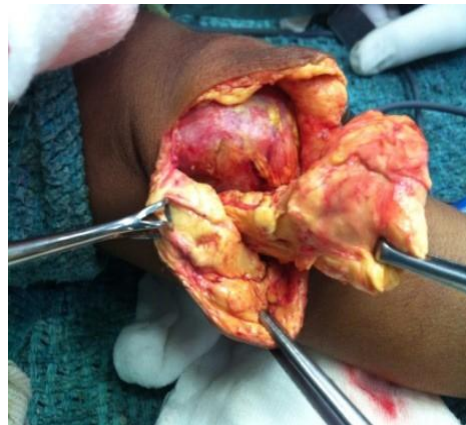


Figure 8.

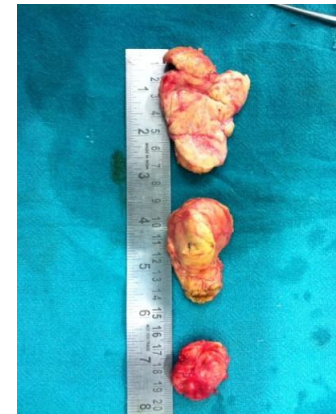

Figure 9.

laboratory findings. Management includes both medical and surgical treatments. Patient was put on tablet Atorvastatin 10mg daily along with a low fat diet. The bigger, cosmetically disfiguring lesions around the knees and the elbows were surgically excised (Fig7, 8 and 9) at the outset as literature suggests their resistance to medical treatment. Subsequent follow-up showed gradually improved lipid profile. Last follow up at 1yr, the kid showed decrease in size of existing lesions with no recurrence or appearance of any new lesion. His lipid profile also returned to normal.

DISCUSSION

The term 'Xanthomas' was coined by Frank Smith in 1869 and they represent localised infiltrates of lipid (cholesterol and cholesterol esters) containing histiocytic foam cells in the skin similar to the changes observed in the blood vessels of atherosclerotic patients. Based on

where they are found on the body and how they develop, xanthomas can be Xanthelasma palpebrum, Tuberosus xanthomas, tendinous xanthomas, Eruptive xanthomas Plane xanthomas, Diffuse plane xanthomatosis, Xanthoma disseminatum etc. The significance of a xanthoma lies in the fact that it is associated with systemic diseases like hypo-thyroidism, biliary cirrhosis, diabetes mellitus, nephrotic syndrome, monoclonal gammopathy (Black MM et al., 1998). But more significantly it can be the only early indicator of a serious underlying lipid abnormality.

Familial hypercholesterolemia (FH) is an autosomal dominant disorder that causes severe elevations in total cholesterol and low-density lipoprotein cholesterol (LDLc). FH in heterozygous state occurs with a prevalence of approximately 1 in 500 individuals, manifesting clinically between third to sixth decades without tendinous and interosseus xanthomas. In contrast, FH with homozygous state occurs very rarely with a prevalence of 1 in million persons. The LDL

receptors affect the serum cholesterol levels directly. They are either absent or grossly malfunctioning in FH. LDLc is removed from the plasma in the heterozygous state at two-third of normal rate, resulting in two to three fold elevation of LDLc i.e., around 300 mg/dl, whereas in homozygous state, it is removed at one-third of normal rate resulting six to eight fold elevation of plasma LDL i.e., 700 mg/dl (Lahiri BC and Lahiri K, 2000). Clinically the homozygous individuals develop arcus juveniles and cutaneous xanthomas during early childhood and cardiovascular abnormalities in the second or third decade of life. Xanthomas are seen in 40-50% patients of Type IIa hyperlipoproteinemia. Tendinous xanthomas (40-50% cases) and xanthelasma (23%) are most common, with tuberous xanthomas in 10-15% and intertriginous plane xanthomas occurring occasionally (Parker F, 1985). Intertriginous xanthomas are thought to be diagnostic of type II hypercholesterolemia (Kumar H et al., 1999). This patient very high level of total cholesterol and LDL cholesterol with multiple types of xanthomas including tendinous, tuberous and palpebral though not at the rare plane inter-digital lesions, with an onset in first decade of life. The work up should include search for an underlying cause and the search for cardiovascular complications like myocardial infarction, stroke, peripheral vascular disease etc. The mainstay of the treatment is medical, aimed at treating the underlying disease or the lipid disorder, thereby reducing xanthomas and risk of cardiovascular calamities. It includes drugs like HMG-coenzyme A reductase inhibitors (statins), fibrates, nicotinic acid, cholestyramine etc. besides, dietary restrictions (Illingworth DR et al., 1998).

CONCLUSION

The role of an orthopaedician is not limited to diagnosing the condition and referring it to the concerned department, but sometimes the lesions require surgical excision. Many a times, such patients come to orthopaedicians for the obvious lesions overlying the joints and then it becomes the duty of that surgeon to look beyond the obvious to be able to diagnose the more attention deserving causative pathology and help prevent fatal outcomes. Also, large disfiguring lesions take too long or don't at all reduce warranting surgical removal even if asymptomatic, because their presence is often demoralizing to school going kids while excision is instantaneously satisfying.

REFERENCES

- Black MM, Gawkrödger DJ, Seymour CA, Weismann K (1998). Metabolic and nutritional disorders. *In: Textbook of Dermatology*, 6th edition. Eds. Champion RH, Burton JL, Burns DA, Breathnach SM. Oxford Blackwell Science Ltd. Pp2600-2613.
- Parker F (1985). Xanthomas and hyperlipidemias. *J. Am. Acad. Dermatol.* 13: 1-30.
- Kumar H, Karthikeyan, Thappa DM, Sivaraman, Sridhar MG (1999). Koebner Phenomenon in Type II hypercholesterolaemia. *Indian J. Dermatol.* 44:140-142
- Lahiri BC, Lahiri K (2000). Homozygous hypercholesterolemia. *Indian J. Dermatol.* 45:205-7
- Illingworth DR, Bacon SP, Larsen KK (1998). Long term experience with HMG CoA reductase inhibition in the therapy of hypercholesterolemia. *Atherosclerosis Rev.*8:161-87.